

Duodenal mucosal resurfacing (DMR) as a new endoscopic treatment for type 2 diabetes (T2D): Safety and proof-of-principle cohort study

Alan D. Cherrington¹, Manoel P. Galvão Neto², Leonardo Rodriguez³, Pablo Becerra³, Patricia Rodriguez³, Paulina Vignolo³, Harith Rajagopalan⁴, Jay Caplan⁴ and Geltrude Mingrone⁵

¹Vanderbilt University Medical Center, USA; ²Gastro Obeso Center, Brasil; ³CCO Clinical Center for Diabetes, Obesity and Reflux, Chile; ⁴Fractyl Laboratories, Inc., USA; ⁵Catholic University of Rome, Italy

Introduction

- Interventions that prevent nutrient contact with the duodenum (i.e. bariatric surgery, intra-luminal sleeve) improve glycemic control in type 2 diabetes (T2D)
- Duodenal mucosal resurfacing (DMR) is a non-invasive, endoscopic procedure that potentially offers similar metabolic benefit through ablation of the duodenal mucosa surface

Objectives

- First-in-man, proof-of-concept study to assess procedural safety and glycemic control after DMR

Methods

- A minimally invasive, upper endoscopic procedure employing novel balloon catheters (Revita™ DMR System, Fractyl Laboratories, USA) was used to ablate either a short segment (SS-DMR; <6 cm ablated) or long segment of duodenum (LS-DMR; >9 cm ablated) in adult patients with poorly controlled T2D
 - HbA1c > 7.5% on at least 1 oral anti-diabetic agent
- Procedural steps: duodenal sizing → saline expansion of sub-mucosa → hydrothermal ablation of superficial mucosa
- All procedures were performed at a single center in Santiago, Chile by trained endoscopists
- 2-week, low calorie, graduated diet for all patients post-procedure (liquids → soft → puree)
- No specific recommendation on management of anti-diabetic medication post-procedure

Results

- 44 consecutive patients enrolled, 39 treated
 - 28 received LS-DMR (mean length ablated: 9.3 cm)
 - 11 received SS-DMR (mean length ablated: 3.4 cm)
- Baseline (mean): age=53.3 y; weight=84.5 kg; HbA1c=9.5%; fasting plasma glucose (FPG)=184 mg/dL
- 5 excluded patients: 4 did not receive DMR (2 failed screening endoscopy, 1 tortuous anatomy, 1 procedure duration), 1 excluded for anti-GAD +

Safety & Tolerability

- Procedure well tolerated with minimal GI symptoms
- 3 patients experienced duodenal stenosis that required endoscopic balloon dilation, with good resolution
- No GI bleeds, perforation, pancreatitis evidence of malabsorption or hypoglycemia
- Follow up endoscopies indicate full mucosal healing by 1 month post-procedure (**Fig. 1**)

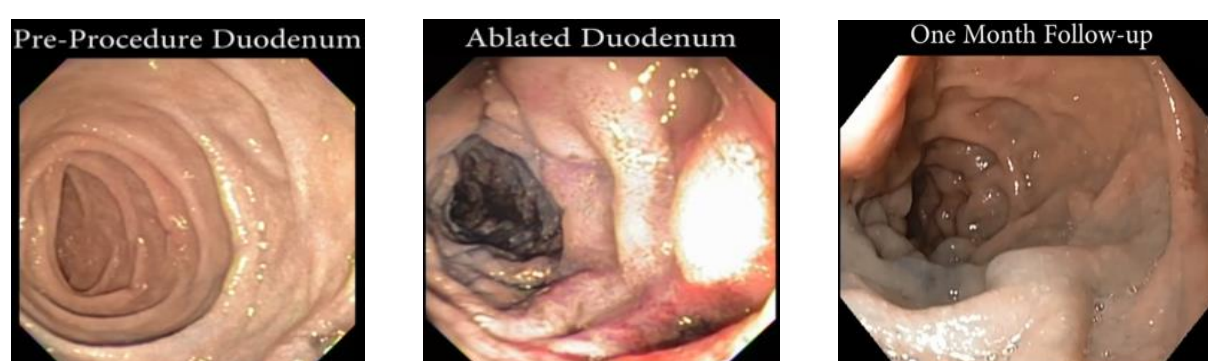


Fig. 1. Full mucosal healing is evident 1 month after duodenal mucosal resurfacing.

Study funding: Fractyl Laboratories, Inc.
 Disclosures: AC, MGN, LR, PB, PR, PV, GM: Paid scientific advisors to Fractyl. HR, JC: employees of Fractyl.
 Contact: alan.cherrington@vanderbilt.edu

Efficacy

- HbA1c reduction of 1.2% at 6 months in full cohort (**Fig. 2**)
- LS-DMR had more potent glycemic effects
 - 2.5% reduction in baseline mean HbA1c with LS-DMR at 3 months post-procedure vs 1.2% with SS-DMR (p<0.05)
 - Early and sustained improvement in FPG (**Fig. 3**)
- Greater DMR effects in patients on stable medications (**Fig. 4**)
- Modest weight reduction (2-4%), but no apparent correlation between degree of weight loss and glycemic improvement

Fig. 2. Reduction in HbA1c after DMR procedure

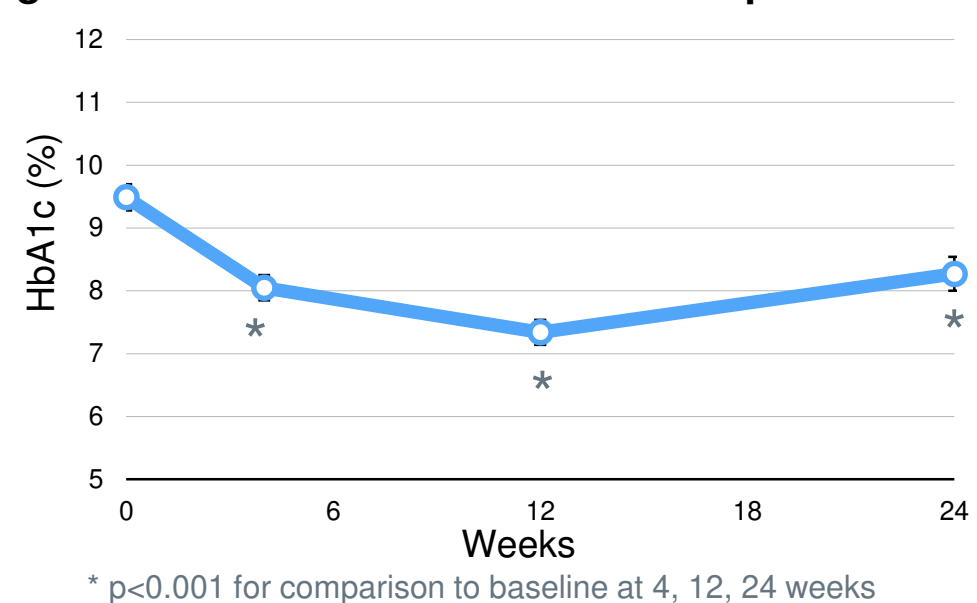


Fig. 3. Fasting plasma glucose by ablation cohort

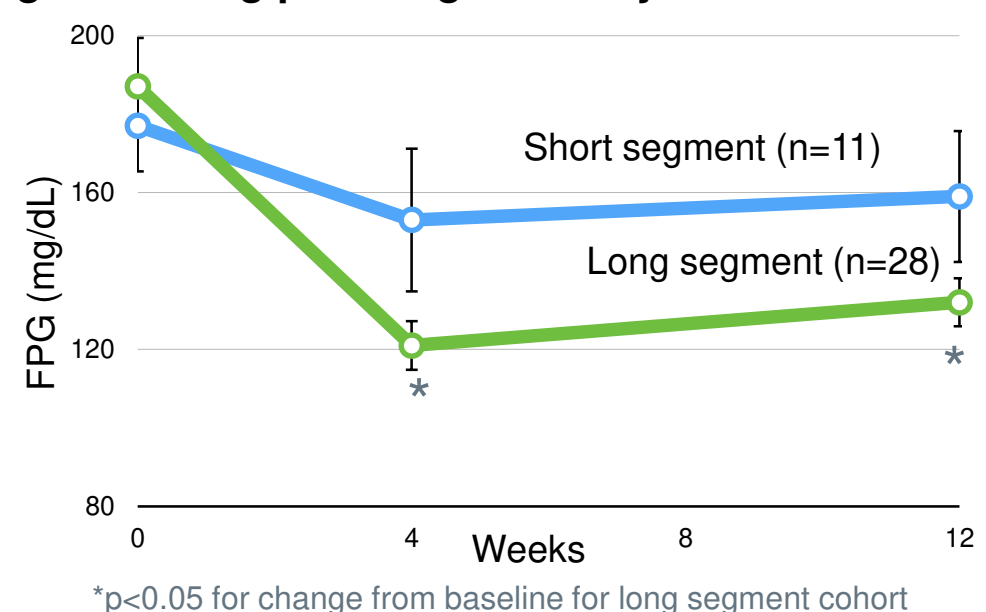
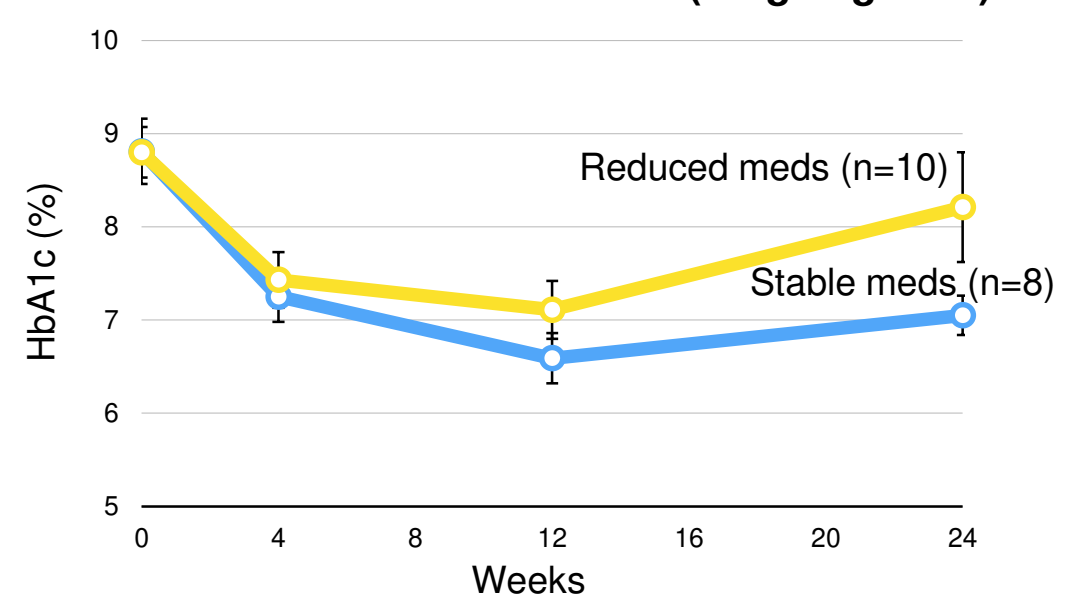


Fig. 4. Changes in concomitant anti-diabetic medication use and DMR outcome (long segment)



Data on long segment patients with baseline HbA1c 7.5-10% shown. 1.8% reduction in HbA1c among those on stable anti-diabetic medicines.

Conclusions

- In this first-in-man study, single procedure DMR substantially improves glycemic control in patients with T2D, with acceptable safety and tolerability
- Upper GI intervention may represent a novel way to improve glycemia in T2D